

Maxillofacial Radiographic study of Gardner's syndrome presenting with odontogenic myxoma: A rare case report

Loufi Salti¹, Michael Rasse², Khaled Al-ouf³

SUMMARY

Gardner syndrome is an autosomal dominant disease. It is characterized by a combination of familial adenomatous polyposis (FAP) of the intestine with extraintestinal changes as multiple osteomas and fibromas. Odontogenic Myxoma is a benign, aggressive intraosseous neoplasm. We report a rare case of a 14-year-old male patient with Gardner's syndrome and odontogenic myxoma, which involved the entire left half of the mandible, resulting in a gross facial deformity, within a span of one year.

Keywords: Gardner syndrome, odontoma, odontogenic myxoma, radiography.

INTRODUCTION

Gardner's syndrome (GS) is an autosomal dominant inherited disease characterized by the presence of polyposis coli, osteomas and multiple hard and soft tissue tumors. It was demonstrated that the syndrome to be caused by the mutation in the adenomatous polyposis coli locus (APC gene) located on chromosome 5q21 (1). Furthermore, there are more than 1400 different mutations of this gene (2). The mutant area of APC gene determines the extracolonic manifestations, number and potential malignant and progressing of the colonic polyps (3). The Gardner's syndrome has an incidence ranging between 1 in 4.000 and 1 in 12.000 births (4). Approximately 70% of patients present dental anomalies such as unerupted, missing, supernumerary teeth, hypercementosis, odontoma, dentigerous cyst, and caries (5). Roots of posterior teeth may be fused, long and tapered. Generally, osteomas precede the clinical and radiographic evidence of colonic polyposis. Therefore, Presence of osteomas is required to make the diagnosis of (GS). The most common cutaneous finding in patients with (GS) is epidermoid cysts. Gastric fundic gland and duodenal polyps occur in 90% of patients (6). Odontogenic

myxoma (OM) is classified as a locally invasive, rare nonencapsulated, benign tumor of the jaws. OM is described as a slow growing tumor consisting of an accumulation of mucoid with little collagen. OM presents in 3% to 6% of the odontogenic tumors. The (WHO) considered the (OM) to be an odontogenic tumor on the basis of its site with or without odontogenic epithelium, which is almost exclusive to the tooth-bearing portions of the jaws (7). The origin of OM is believed to be from the dental papilla, follicle, and periodontal ligament (8). The annual incidence of OM is 0.07 per million (9). The occurrence of OM in the mandible is higher when compared to the maxilla (2:1) with slight predilection to females. OM affects patients between 10-50 years.

CASE REPORT

A 14-year-old male patient was referred on December 2014 by his dentist for a slight swelling on the left side of his face. The clinical examination showed a slight painless swelling of his left mandible. The oral mucosa was normal, and the regional lymph nodules were not palpable. The TMJ examination was normal with no deviation of the mandible. There was no complaint of digestive problem, no trigeminal paresthesia, and the facial nerve function was preserved. The skin was normal and no cysts were noted. Following evaluation, a panoramic radiograph (DPT) was obtained (Figure 1). The panoramic radiograph revealed multiple impacted teeth, unerupted and retained deciduous teeth.

¹Department of restorative and periodontology, University of Greifswald, Germany.

²Department of oral & maxillofacial surgery, University of Innsbruck, Innsbruck, Austria

³Private practice, Damascus, Syria

Address correspondence to Loufi Salti, Department of restorative and periodontology, University of Greifswald, Friedrich Ebert Str. 69, 34119 Kassel, Germany.
E-mail address: dr.l.salti@gmail.com

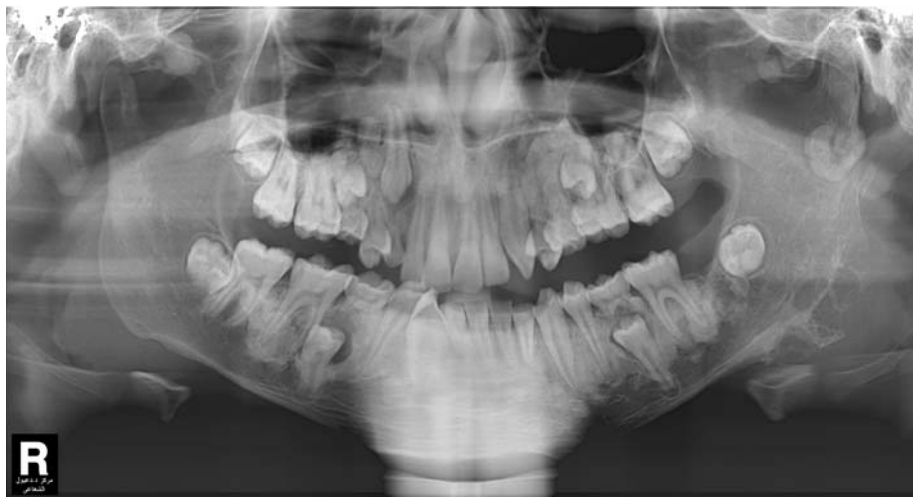

Fig. 1. Panoramic radiograph shows unerupted teeth, osteoma at the left ascending ramus and in the left zygomatic–maxillary process. Multilocular lesion is at the left mandible angle

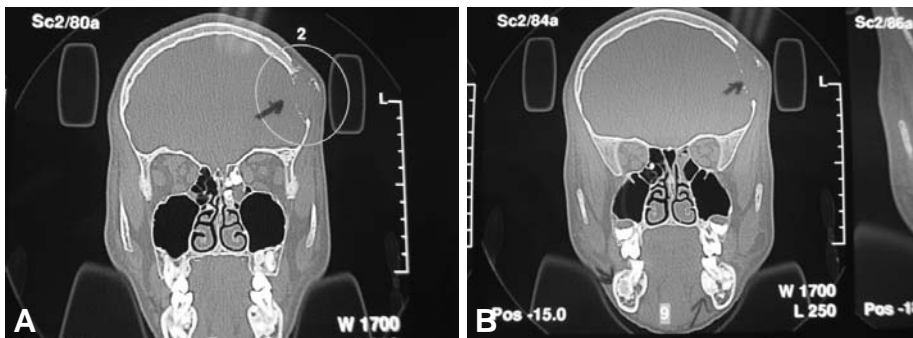


Fig. 2. Coronal CT views show osteomas in the left maxillary sinus, left zygomatic bone, ethmoidal cells and sphenoid bone

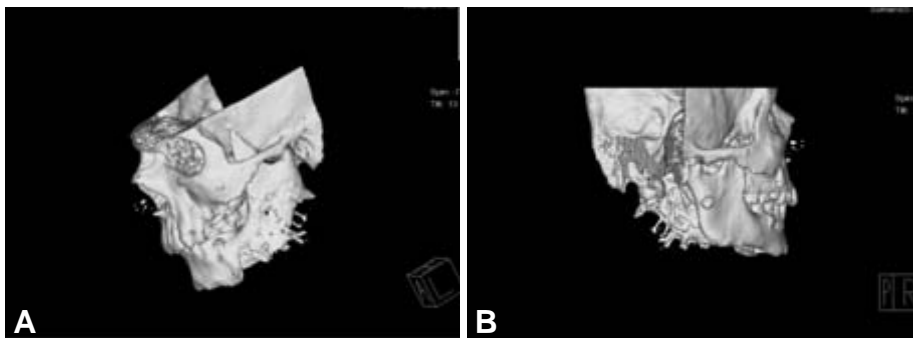


Fig. 3. Three-dimensional reconstruction CT scans demonstrating the osteomas in the left zygomatic bone (A) and in the right ascending ramus (B)

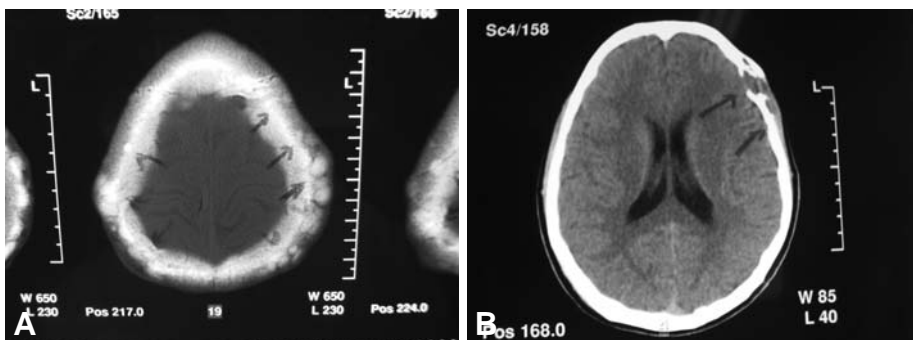


Fig. 4. A – axial CT views reveal cottonwool patches appearance in the skull vault (arrows). B – the brain appeared within normal limits.

Additionally, non-corticated, conglomerates of indistinct radiopacities structures were noted apical to the roots of first mandibular molars and maxillary premolars and molars and in the ascending ramus. A non-corticated, distinct, tooth-like radiopacity was located between the right maxillary first premolar and canine. A well-defined, non-corticated, radiopaque mass was noted in the left zygomatic–maxillary process. Moreover, a multilocular radiolucency area having “soap bubble” pattern was noted at the left angle of the mandible. It has a smooth, well defined margin, scalloped and of variable cortication. Fine septa were seen and the inferior cortex was thinned. The left second lower molar was missing. The roots were neither displaced nor resorbed. To determine the exact location of the lesion, a CT was performed. The Coronal CT demonstrated unerupted teeth and several hyperdense areas in the mandible and left maxilla apical to the roots and in the left ascending ramus (Figure 2). The three-dimensional reconstruction of CT clearly revealed the presence of multiple osteomas in the left maxillary sinus, left zygomatic bone, ethmoidal cells and right ascending ramus (Figure 3). Additionally, the coronal CT revealed partial destruction of the facial bone. Brain CT revealed haphazard deposition of sclerotic bone in the skull vault producing cottonwool patches appearance (Figure 4 A). The brain appeared within normal limits (Figure 4 B). The radiographic findings could be part of (GS). The patient was referred to further investigations. Thyroid ultrasound

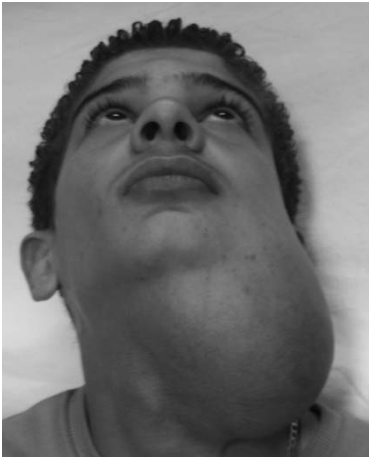

Fig. 5. Photo of the patient

demonstrated homogeneous, smooth and regular margins. Eleven polypectomy were carried out. The proctosigmoidoscopy ascertained intestinal polyps. The colon biopsy reported multiple tubular adenomas. Ophthalmic evaluation indicated absence congenital hypertrophy of retinal pigment epithelium (CHRPE).

The patient returned on November 2015 with gross facial asymmetry and considerable painless, swelling of the left side of the mandible measuring (10×7) cms, extending from the parasymphysis to the angle of the mandible (Figure 5). The oral examination revealed a large, firm and tenderness swelling on the left posterior mandibular region involving the buccal mucosa with laterally jaw expansion and obliterating the buccal sulcus. The mucosa overlying the swelling area was intact. Mouth opening was 10 mm. The patient referred to radiographic investigations. The (DPT) showed multilocular radiolucency in the body of the left mandible, extending from the mesial root of the left first molar to the unerupted third molar and from the upper border of the alveolus towards

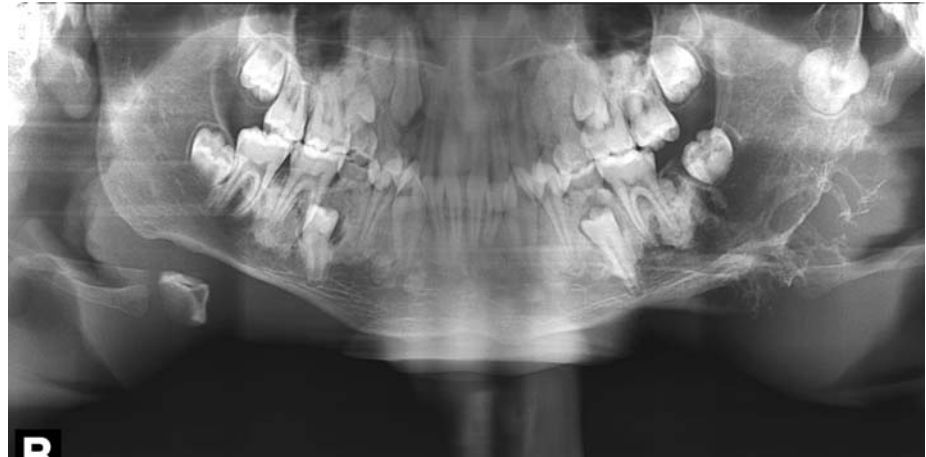

Fig. 6. Panoramic radiograph demonstrates multilocular radiolucency in the body of the left mandible extending from the mesial root of the left first molar to the unerupted third molar

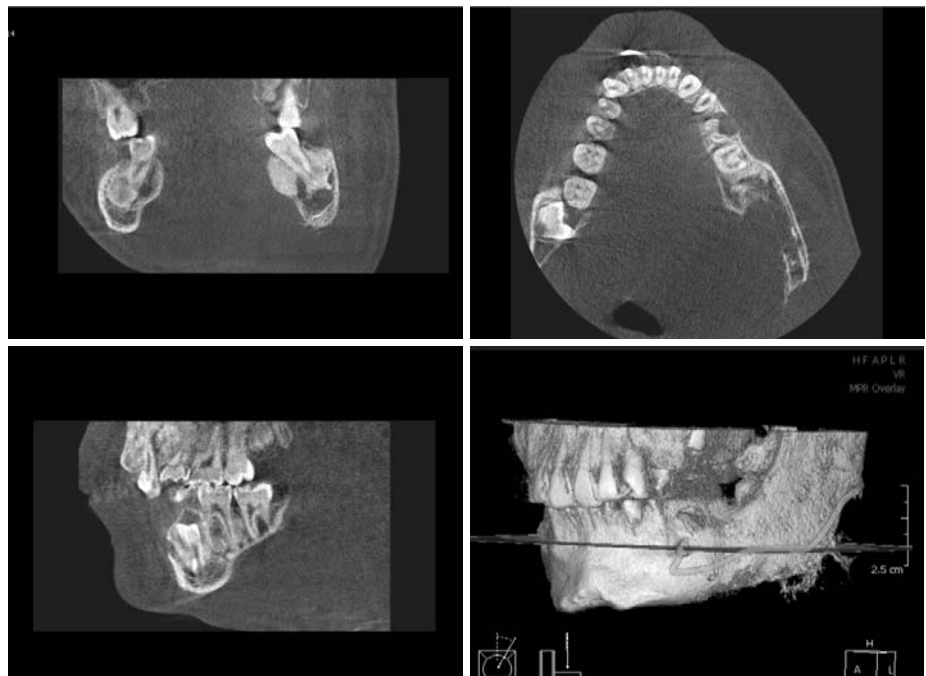


Fig. 7. MPR and volumetric views of the mandible shows loculated irregular radiolucency and well – defined corticated margin in the body of the left mandible (axial). The coronal and sagittal views reveal bone destruction at the left body of the mandible and the ascending ramus.

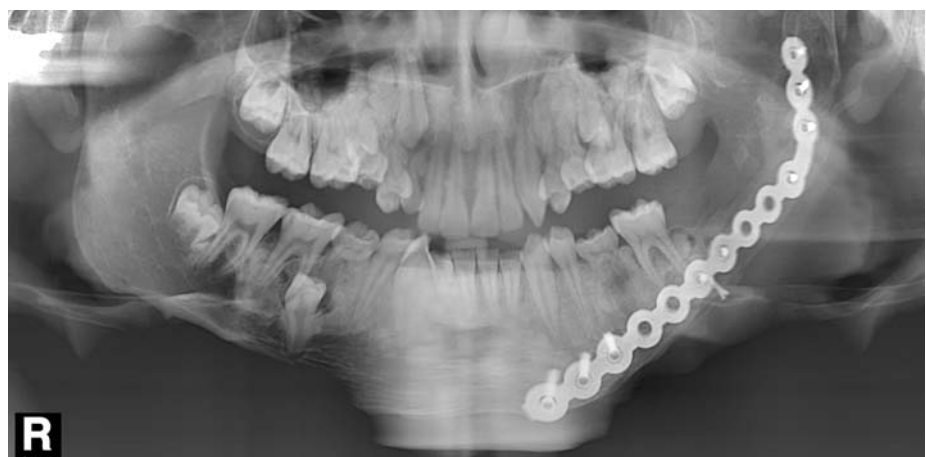

Fig. 8. postoperative panoramic radiograph after one month



Fig. 9. The excised tumor

the lower border (Figure 6). The multilocular radiolucency has a smooth, scalloped, well-defined margin, and of variable cortication. Furthermore, the lesion consists of several small lobules, and fine radiopaque septa within the lesion create the multilocular giving a "soap bubbles" appearance. The axial CBCT showed loculated irregularly shaped radiolucency with well-defined corticated margin in the body of the left mandible (Figure 7). Within the main radiolucency there are several bony septa forming right angle against margin. The coronal and sagittal images revealed extensive bone destruction at the left body of the mandible and the ascending ramus (Figure 7). The patient was referred to the hospital.

The surgical operation was achieved under general anesthesia. Two incisions were planned. The horizontal incision extends from the ear to the chin below the inferior border of the left mandible 3 cm. The vertical incision was in the tumor including layers of the skin. The tumor was isolated from the surrounding tissue followed by hemostasis the blood vessels supplying the tumor. The tumor was removed with the integrated bone at left angle of the mandible. The submandibular gland and its channel were eradicated. Curettage the destructive bone tissue led to large bone loss at the left angle of mandible. The impacted left lower first premolar was extracted. The left hyperplastic coronoid process was excised, because it obstructs the mandible movement. A bone graft (10 cm) was taken from the vertebral end of the seventh rib and adapted according to the left body and angle of the mandible by thoracic surgeon. The bone graft was fixed by reconstructive plate. (Figure 8) and fixed with 9 screws. The subcutaneous tissues were sutured by (000) Vicryl sutures. A negative pressure absorbent drain was inserted in surgical site. The

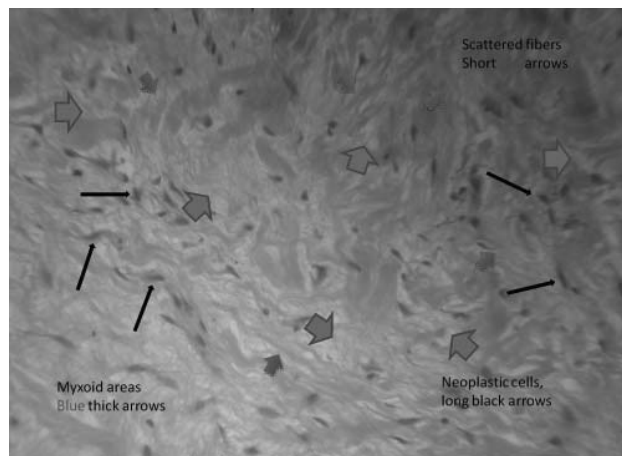


Fig. 10. Micro pathology description. The main lesion showed a connective tissue filled with randomly oriented stellate spindle-shaped and round cells (black arrows) with slightly eosinophilic cytoplasmic processes extending from the centrally placed nucleus. Cells are dispersed in an abundant mucoid or myxoid stroma (blue arrows) that contains only a few collagen fibers (red arrows) (HE×200).

wound was sutured by (00000) nylon sutures. The tumor weighted 2100 grams (Figure 9).

The surgical specimen showed a connective tissue filled with randomly oriented stellate spindle-shaped and round cells with slightly eosinophilic cytoplasmic processes extending from the centrally placed nucleus. Some randomly scattered thick collagen fibers were detected. No malignancy could be detected. The resection margins were free of tumour (Figure 10).

DISCUSSION

This is a rare case of Gardner syndrome associated with gross facial asymmetry and extensive bone destruction at the left body of the mandible and the ascending ramus as a result of unusual OM. The patient presented only for dental and facial cosmetic issues and without gastrointestinal symptoms. The remarkable feature of this patient was neither teeth displacement nor root resorption was noted. (GS) represents a disease that affects multiple systems. Both genders are affected equally, with a uniform worldwide distribution (10). Symptoms may present by the end of 2nd decade of life. Neural, cutaneous and bone abnormalities develop approximately 10 years prior to polyposis (11). Therefore, radiographic recognition of osseous lesions in (GS) can lead to early detection of polyps before they undergo any malignant differentiation. However, in our case the polyps were already asymptomatic at the time of diagnosis. Polyp formation starts at puberty but diagnosis is usually in the third decade.

Osteomas are the oral and maxillofacial hallmark of (GS) and manifest earlier than polyposis. The most common location is the mandible, but they may occur in the skull, long bones, and paranasal sinus cavities (12). Radiographically, osteoma is mostly characterised by a round or oval radiopaque well-circumscribed mass attached by a broad base or pedicle to the affected cortical bone (13). In our case, the odontomas were compact according to the radiographic appearance. Takeuchi *et al.* found oral and maxillofacial lesions in 22 of 23 patients with (GS) (14).

A finding of three or more osteomas has been suggested as a screening method for (GS). In the present case, multiple osteomas were found in left maxillary sinus, left zygomatic bone, ethmoidal cells and sphenoid bone. Treatment of osteomas and odontomas encountered in (GS) depends on either the symptomatic or cosmetic nature of the findings. For our case, no treatment is found to be necessary for the odontomas. In our study, the incidental odontoma, unerupted teeth and OM encountered in (DPT), followed by an osteoma in the CT views have raised suspicion for a presumptive diagnosis of (GS). The colonoscopic biopsy performed from polyps confirmed the diagnosis. The notable feature of this patient was the early manifestations of head lesions and intestinal polyps. The genetic screening is considered the most effective method for demonstrating mutated APC gene in relatives of patients with (GS) (12).

It is known that (GS) is inherited in an autosomal dominant fashion. Thus, the patient's family members should also be screened for polyps. However, no other individual in the patient's family has ever had this disorder. Odontogenic myxoma (OM) is defined as a nonencapsulated benign tumor and occurs almost exclusively in the jaws (15). The large OMs display bony perforation with subsequent invasion into the soft tissues and were also observed in our patient. OM may associate with unerupted, displacement or congenitally missing teeth. The patients usually complain paresthesia, mobility of teeth and ulceration, but none of these features were appreciated in the present case.

OM described as a slow growing tumor consisting of an accumulation of mucoid ground substance. However, rapidly growing (OMs) as in our case are extremely rare and have been reported in the literature (16). It has been reported that OM rarely crosses the midline (17). Expansion of buccal and lingual cortical plates of the mandible may occur occasionally and can be extensive, involving half of the maxilla or mandible including the ramus

and the condyle (17). External and internal cortical displacement can be very evident, with bone destruction and soft tissue protrusion, as seen in the CT of our case. It is reported that root resorption may occur although rare. However, displacement of teeth is rather common (17), which were not noted in our case. The correlation between the size of the lesions and their locularity was reported (18). Our study showed a multilocular OM reached size larger than 40 mm. This finding corresponds with study of Noffke *et al.* In order to manage these tumors appropriately, it is imperative to determine their extent (19). The CBCT and (MRI) imaging have been found to be superior to conventional radiographs when demonstrating the intraosseous extent of the tumor, cortical perforation, soft tissue involvement, and extent (20). Radiographically, (OM) often show multilocular radiolucencies of "honey comb", "soap bubble" or "tennis racquet" appearance which helps in differential diagnosis (OM) from malignant tumors arising centrally within the jaw bones (15). The malignant tumors usually cause massive bone destruction without compartments formed by bony septa. In our case, the DPT demonstrated multi expansion radiolucent lesion with thin bony septa in the area of bony destruction giving the multilocular radiographic appearance and is described as having a "soap bubble". The radiographic differential diagnosis includes ameloblastoma, odontogenic fibroma, dentigerous cyst, central giant cell granuloma, and fibrous dysplasia (21). Treatments of OMs vary from local excision, curettage or enucleation to radical resection. Complete surgical removal, using curettage and peripheral ostectomy alone is not sufficient as the lesion is not encapsulated and because the myxomatous tissue infiltrates adjacent bone (22). These characteristics may explain the high rate of recurrence of myxomas, where simple enucleation and curettage alone can have recurrence rates which range from 10 to 33% (22). In our case, the tumor was completely removed. In large OMs, it is advisable to follow up the patients closely at least 2 years to establish disease free situation (23).

CONCLUSION

This case underlines the difficulty in establishing a correct diagnosis, which requires interaction between radiologist, surgeon and pathologist.

CONFLICTS OF INTEREST

None to declare

REFERENCES

1. Trehan AK, Osborn H, Trehan SK, Aggarwal O. Gardner's syndrome: a case report. *J Emerg Med* 1995; 13(4):489-92.
2. Gu GL, Wang SL, Wel XM, Bal L. Diagnosis and treatment of Gardner's syndrome with gastric polyposis case report and review of literature, *World J Gastroenterol* 2008;14:2121-3.
3. Fotiadis C, Tsekouras DK, Antonakis P, Sfiniadakis J, Genetzakis M, Zografos GC. Gardner's syndrome: a case report and review of the literature. *World J Gastroenterol* 2005; 11(34):5408-11.
4. Jonathan Butler, Claire Healy, Mary Toner, Stephen Flint. Gardner syndrome—review and report of a case. *Oral Oncology Extra*. 2005; 41:89–92.
5. Davies AS. Gardner's syndrome: A case report. *Br J Oral Surg*. 1970; 8:51–7.
6. van Epps KJ, Kuszyk BS, Hofmann LV, Fishman EK. Epidermoid inclusion cysts seen on CT of a patient with Gardner's syndrome. *AJR Am J Roentgenol*. 1999; 173:858 – 859
7. Kramer IRH, Pindborg JJ, Shear M. *Histological Typing of Odontogenic Tumours*. 2nd edition, Springer Verlag: Berlin 1992:p.23.
8. Sapp J P, Eversole L R, Wysocki G P, Duncan L L (Ed). *Contemporary oral and maxillofacial pathology*. Pp147-148. St. Louis, Mosby: Year Book, Inc, 1997
9. Simon EN, Merckx MA, Vuhahula E, Ngassapa D, Stoeltinga PJ. Odontogenic myxoma: A clinic pathological study of 33 cases. *Int J Oral Maxillofac Surg*. 2004; 33:333-7.
10. Kamel SG, Kau CH, Wong ME, Kennedy JW, English JD. The role of Cone beam CT in the evaluation and management of a family with Gardners syndrome. *J Craniomaxillofac Surg*. 2009; 37:461–8.
11. Nandakumar G, Morgan JA, Silverberg D, Steinhagen RM. Familial polyposis coli: clinical manifestations, evaluation, management and treatment. *Mt Sinai J Med* 2004; 71(6):384-91.
12. Wijn MA, Keller JJ, Giardiello FM, Brand HS. Oral and maxillofacial manifestations of familial adenomatous polyposis. *Oral Dis* 2007; 13:360-365.
13. Bilkay U, Erdem O, Ozek C et al. Benign osteoma with Gardner syndrome: review of the literature and report of a case. *J Craniofac Surg*. 2004; 15: 506-509.
14. Takeuchi T, Takenoshita Y, Kubo K, Iida M. Natural course of jaw lesions in patients with familial adenomatosis coli (Gardner's syndrome). *Int J Oral Maxillofac Surg*. 1993; 22:226-30.
15. Simon EN, Merckx MA, Vuhahula E, Ngassapa D, Stoeltinga PJ. Odontogenic myxoma: A clinic pathological study of 33 cases. *Int J Oral Maxillofac Surg*. 2004; 33:333-7.
16. Kaffe I, Naor H, Buchner A. Clinical and radiological features of odontogenic myxoma of the jaws. *Dentomaxillofac Radiol*. 1997; 26:299–303.
17. Chrcanovic BR, do-Amaral MB, de-Andrade Marigo H, Freire-Maia B. An expanded odontogenic myxoma in maxilla. *Stomatologija*. 2010; 12:122–8.
18. Kaffe I, Naor H, Buchner A. Clinical and radiological features of odontogenic myxoma of the jaws. *Dentomaxillofac Radiol*. 1997;26:299–303.
19. Noffke CE, Raubenheimer EJ, Chabikuli NJ, Bouckaert MM. Odontogenic myxoma: review of the literature and report of 30 cases from South Africa. *Oral Surg Oral Med Oral Pathol Oral Radiol Endod* 2007; 104:101-9.
20. MacDonald-Jankowsky DS, Yeung RWK, Li T, Lee KM. Computed tomography of odontogenic myxoma. *Clin Radiol* 2004; 59:281-7.
21. Kim JY, Park GM, Cho BH, Nah KS. Odontogenic myxoma: report of 2 cases. *Korean J Oral Maxillofac Radiol* 2002; 32: 231-4.
22. Leiser Y, Abu-El-Naaj I, Peled M. Odontogenic myxoma - A case series and review of the surgical management. *J Craniomaxillofac Surg* 2009; 37:206-9.
23. Li TJ, Sun LS, Luo HY. Odontogenic myxoma: A clinicopathologic study of 25 cases. *Arch Pathol Lab Med*. 2006; 130:1799–806.

Received: 19 11 2016
Accepted for publishing: 26 06 2018